



# HISTOLOGICAL AND HISTOMORPHOMETRICAL POSTNATAL DEVELOPMENTAL STUDY OF ADRENAL GLAND IN AWASSI SHEEP (*OVIS ARIS*)

Al-Zubaidi K.A<sup>1</sup> and Shaimaa Mahdi Nasif<sup>2</sup>

<sup>1</sup>Department of Anatomy and Histology, College of Veterinary Medicine, Al-Qasim Green University, Babylon, Iraq.

<sup>2</sup>Ministry of Agriculture, Veterinary Directorate, Babylon, Iraq.

## Abstract

The present study was designed to identify the histological structures of adrenal gland in postnatal ages, which divided into five ages (one day, one month, two month, six month and two years). The adrenal glands were collected from AL-Nijaf and Hilla slaughter house and prepared for histomorphological study. Paraffin sections for all samples were fixed in 10% neutral buffered formalin for histological purposes and using routine (Harries Hematoxylin and Eosin, Periodic acid Schiff (PAS) and Massons Trichrome Staining) for histological components. The adrenal glands were a pair of compound, flattened endocrine organs located in the retroperitoneal tissue along the medial cranial poles of the kidneys. The color of the glands were red – brown. Histologically, adrenal gland showed cortex and medulla enclosed by clear capsule. The cortex was includes (zona glomerulosa, zona fasciculate and zona reticularis). The present study has concluded that the size of the capsule and cortex increased with age progressed to increase in medulla thickness.

**Key words:** Histological, Postnatal, Adrenal gland, Awassi sheep.

## Introduction

Awassi was the most common breed of sheep in the east of Mediterranean. It was the main sheep breed in Iraq and Syria, the only native breed in Jordan (Hailat, 2005). The Improved Awassi strain of the breed was known to have the highest milk production after the East Friesian. Awassi also resistance to diseases and parasites, tolerance to extreme temperatures beside its high milk producing and growth abilities (Gürsoy *et al.*, 1993). The adrenal gland was called the suprarenal gland because of its anatomical position above the kidney. They were two in number, the right and left adrenal glands. The two anatomical distinct units of adrenal cortex and medulla were originated from embryological mesoderm and neural crest ectoderm respectively and were surrounded by a connective tissue capsule (Junqueira *et al.*, 1998, McDonald *et al.*, 2003). The adrenal cortex was subdivided into three or four distinct zones of epithelial cells. (Bacha and Wood, 1990, Dellman, 1993). The cortical and medullary cells were different in their secretory functions. The adrenal cortex produces most

of the mineralo-corticoids and glucocorticoids whereas the epinephrine and nor-epinephrine are secreted from the medulla in response to intense stress reactions (Humayun *et al.*, 2012).

The project was targeted to investigate histological structures of adrenal glands of local sheep Awassi and giving basic information for researchers that experiments in many veterinary fields.

## Materials and Methods

The study was carried out on 20 healthy adrenal gland of local awassi sheep of both sex. The specimens were obtained from slaughterhouse, divided into five ages (one day, one month, two month, six month and two years) with four specimen for each age. The adrenal glands of each animal were collected immediately after the slaughter, then the gland were wished with distilled water and the samples were put in a plastic container with 10% neutral buffer formalin solution for 24 hours, then brought to the laboratory for further processing of routine paraffin section. The ages of the sheep were determined by

dentition (Chibuzo, 2006).

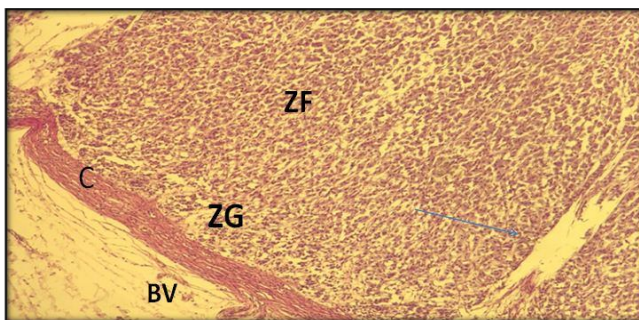
The specimen were embedded in the solution of paraffin at melting point ranged from (56-58°C) of paraffin bath for four hours, for two changes. Serially, the specimen were sectioned in a plane at (6-7  $\mu$ m) by using rotary microtome. The prepared section were stained with Harries Hematoxylin and Eosin stain, Periodic acid Schiff (PAS) stain and Massons Trichrome Stain.

A computerized program, the statistical package for social sciences (SPSS) version 24 was used to calculate the statistics. The statistical analysis of data for histological parameters had done by, descriptive statistics: Mean and Standard error, Statistical analysis of data was performed on the basis of one-Way, ANOVA of Variance at significant level of ( $P < 0.05$ ) (Field, 2013).

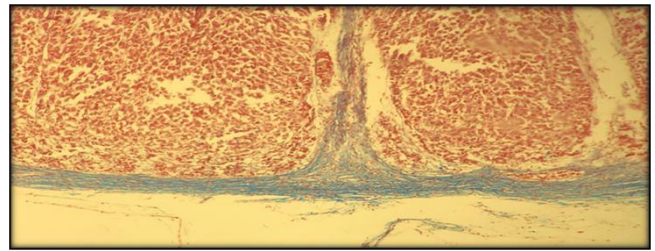
### Results and Discussion

At 1<sup>st</sup> day: The adrenal gland was surrounded by a thin capsule of collagenous and elastic fibers, with blood vessels and nerve, a thin of connective tissues trabeculae were penetrate to the cortex. The cells of cortex organized in cords, zona glomerulosa showed the glomeruli of irregular clusters or cords, the cells were cuboidal with darkly stain nuclei, zona fasciculata was differentiated and seen below the zona glomerulosa. Zona reticularis also could not be seen at this age. The medullary cells were arranged in clusters surrounded by sinusoids lined by endothelial cells, the same characteristic features of large epinephrine (EN) and small norepinephrine (NEN) cells of the previous stage. Ashok *et al.*, (2011) were recorded that the capsule was strongly positive PAS, moderate this reaction in zona glomerulosa and zona fasciculata. (Fig. 1). In the present study the adrenal capsule was also give strong positive for Masson Trichrome (Fig. 2).

At 1<sup>st</sup>, 2<sup>nd</sup> and 6<sup>th</sup> month: The present study were



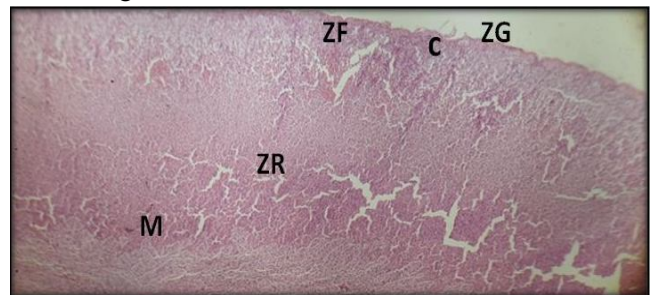
**Fig. 1:** Photomicrograph of adrenal gland in sheep at (one month) showing positive reaction of adrenal capsule (C), zona glomerulosa (ZG) zona fasciculata (ZF), blood vessels (B.V.) and thin trabeculae (arrows). PAS stain. ( $\times 20$ ).



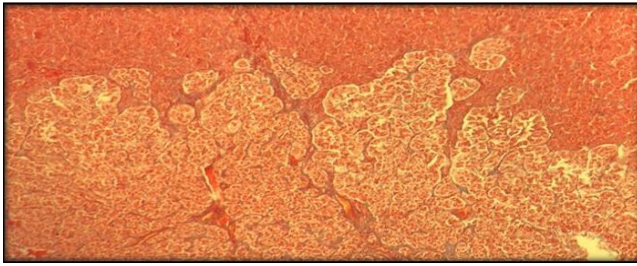
**Fig. 2:** Photomicrograph of adrenal gland in sheep at one day showing strong positive for Masson Trichrome stain reaction of adrenal capsule and trabeculae (blue stain). ( $\times 20$ ).

recorded that the glands of these ages enclosed by a distinct thick capsule of collagenous, elastic and reticular fibers, a trabeculae of connective tissue extend from capsule to the cortex. A blood vessels, nerve ending were present in the capsule. The present study was stated that the zonations (three zones) of adrenal cortex could be differentiated at these ages (1<sup>st</sup>, 2<sup>nd</sup>, 6<sup>th</sup>) months of postnatal life (Fig. 3). Zona glomerulosa had an oval to rounded glomeruli. Each glomerulus surrounded by a trabeculae of capsule content. Between the glomeruli a sinusoids lined by endothelial cells. The cells of this zone were cuboidal with an oval nucleus. The cells of zona fasciculata were columnar with rounded nucleus and acidophilic cytoplasm arranged as a cords in radial direction, surrounded by sinusoidal capillaries. The cells which had binucleated were seen. Similar observations of Prasad and Yadava (1972), AL-Taay (2007) in buffaloes.

The present study were recorded that the zona glomerulosa at 1<sup>st</sup> and 2<sup>nd</sup> months of postnatal life were thicker than the age of 6<sup>th</sup> month. The zona fasciculata was the largest zone occupied approximately about 70 percent of cortex at 6 month of postnatal life. Prasad and Sinha (1981a) reported that the zona fasciculata was narrowest in dog and widest in goat. On the other hand Singh *et al.*, (1986) noted a zona combined of zona fasciculata and reticularis formed a major part of adrenal cortex in goat.



**Fig. 3:** Photomicrograph of adrenal gland in sheep at one month showing capsule (C), three distinct zone, zona glomerulosa (G) zona fasciculata, zona reticularis (R) and medulla. H & E stain ( $\times 10$ ).

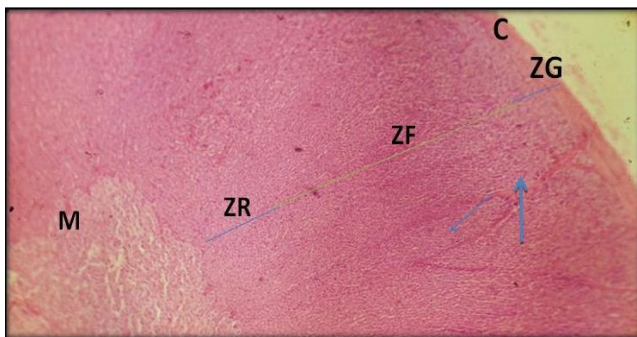


**Fig. 4:** Photomicrograph of adrenal gland in sheep life at six month showing dipping of fibrous content (blue stain) in medulla. Masson Trichrom stain ( $\times 40$ )

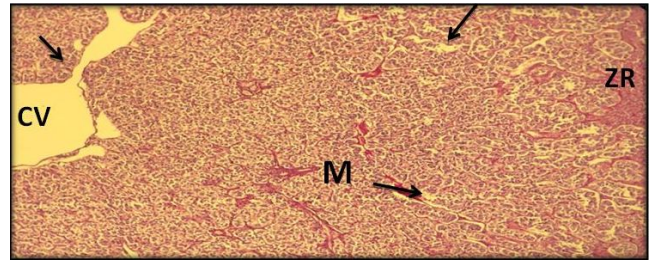
Paul *et al.*, (2016) mentioned that the zona fasciculate had a spongy appearance, due to the cytoplasmic lipid vacuoles left by extraction during routine histological processing. This observation was matched with the present study. However, Singh *et al.*, (1999) recorded that the increased lipid related to the glucocorticoids secretion in buffalo. The zona reticularis had a cord of intercrossing cuboidal cells forming a network. Each cord of it was surrounded by an irregular sinusoids. The histochemical reactions of present study at these ages showed strong PAS positive for capsule, zona glomerulosa and light positive PAS for zona reticularis.

The adrenal medulla at these ages of present study revealed a distinct demarcation of medulla from cortex. It had two distinct layers or zones. The outer epinephrine cellular layer had large columnar cells with eccentric spherical nuclei and granular acidophilic cytoplasm. The inner norepinephrine cellular layer had cells smaller than epinephrine with granular basophilic cytoplasm and centric nuclei, located near the central vein. Similar observations were recorded in goat by Prasad and Sinha (1981b).

Dipping of fibrous content of collagen and reticular fibers from zona reticularis into medulla surrounded the cords of cells were be seen in present study (Fig. 4). Similar findings were recorded in buffalo by Prasad and Yadava (1972) and sheep by Prasad and Sinha (1981b).



**Fig. 5:** Photomicrograph of adrenal gland in sheep at two years showing Capsule (C), three distinct zone Zona Glomerulosa (ZG), Zona fasciculate (ZF), Zona Reticularis (ZR), Medulla (M), Sinusoids (blue arrow) and Trabeculae (arrow). H & E stain ( $\times 10$ ).



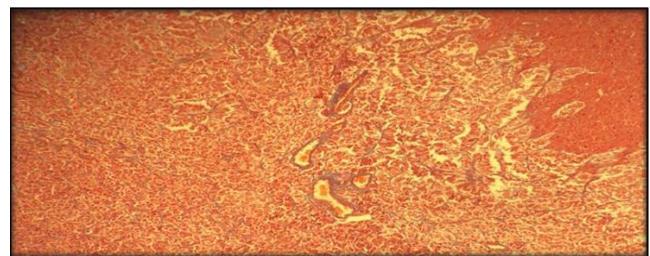
**Fig. 6:** Photomicrograph of adrenal gland in sheep at two years showing medulla with lightly positive reaction of PAS stain (M), zona reticularis (ZR), central vein and irregular sinusoids (arrow), ( $\times 20$ ).

At 2 years ages: The present observations stated that the adrenal gland enclosed by thick capsule.

Three cortical zones were seen in adrenal gland of sheep of present study. Zona glomerulosa, the outer most zone below the capsule consist of glomeruli of spherical cells with the sinusoids.

Below the previous zone, the zona fasciculate were seen as a widest zone of adrenal cortex, composed of columnar cells arranged in radiate columns surrounded the sinusoids. The cells had spherical nuclei with acidophilic cytoplasm and frequent binucleated contained lipid vacuoles with spongy appearance. Paul *et al.*, (2016) in goat were recorded a transitional zone above the zona fasciculate. Under the zona fasciculate the zona reticularis (Fig. 5), the inner most zone of the cortex, had polygonal cells with spherical nucleus in irregular arrangement and anastomosing cords. These findings were in agreement with Bacha and Bacha (2000) in mammals.

The present observations of adrenal medulla in sheep at this age showed avoid or polyhedral groups of cells, arranged in two zones or layers. The outer layer (epinephrine cells) with spherical eccentric nuclei and this represented the major part of medulla. The inner layer was norepinephrine cells, with centrally nucleus. Central vein was seen with irregular sinusoids surrounded the medulla cells (Fig. 6). The connective tissue fibers entering the medulla and surrounding the epinephrine cells were seen in the present study and these fibers also showed positive Masson's Trichrome reactions (Fig. 7).



**Fig. 7:** Photomicrograph of adrenal gland in sheep at two years showing fibers in medulla of positive Masson's Trichrome reactions. ( $\times 20$ ).

**Table 3:** Showing thickness of cortex zones and medulla in sheep life.

Thickness of Medulla (um)	Thickness of Zona reticularis (um)	Thickness of Zona fasciculate (um)	Thickness of Zona glomerulosa (um)	Thickness of Capsule (um)	parameter Day
39.61±3.22	-	45.60±02.33	10.55±0.62	4.75±0.32	1 day
48.33±2.34	27.32±2.31	46.70±3.55	11.60±0.3	6.12±0.42	1 month
90.51±3.66	31.44±3.21	52.60±5.32	12.73±0.69	7.50±0.64	2 month
98.71±3.1	44.22±3.1	61.21±4.33	16.82±0.85	10.50±0.66	6 month
115.3±4.21	59.87±4.3	70.80±5.88	14.55±0.25	8.50±0.70	2 year

These observations were similar to the study of Dellmann (1993) in ruminant.

The overall average of thickness capsule in ages (one day, one month, two month, six months and two years) its (4.75±0.32, 6.12±0.42, 7.50±0.64, 10.50±0.66, 8.50±0.70) um respectively, table 1.

The measurements of the capsular thickness showed a gradual increment till six months, then decrease in thickness at age two years. These increase of the capsule was due to the increase in the fibrous content, blood vessels and nerves and melanin pigments cells (Bacha and Bacha, 2000). Prasad and Yadava (1972) noted a fairly thick capsule rich with blood vessels and nerves in buffaloes.

The overall average of thickness zona glomerulosa in ages (one day, one month, two month, six month and two years) was (10.55±0.62, 11.60±0.3, 12.73±0.69, 16.82±0.85, 14.55±0.25) um respectively table 1. The present study showed this zone increased in thickness gradually in aged (one day, one month, two month, six month) but in aged (two years) was decrease. This observation agreement with Singh *et al.*, (1986) and (Bacha and Bacha, 2000). Mentioned the zona glomerulosa at 1-3 months of age was relatively thicker becoming narrower as the age advances up to 9 months.

The overall average of thickness zona fasciculata in ages (one day, one month, two month, six month and two years) its (45.60±02.33, 46.70±3.55, 52.60±5.32, 61.21±4.33, 70.80±5.88) um respectively table 1. The zona fasciculate was broadest zones of cortex. This zone gradually increases in its thickness from one month onwards. Singh *et al.*, (1986) observed a combined zone of zona fasciculata and reticularis constituting a major part of cortex in goats. The present study showed highly significant differences ( $P \leq 0.05$ ) between different age sheep. These present results were established by other workers, 'Prasad and Sinha (1981a) who reported their micrometrical findings reported that this zone was widest in goat and narrowest in dog and among the cortical zones, zona fasciculata was largest in all the domestic animals.

The hypertrophy and hyperplasia was consequent of secretory function increased as production of hormones to adverse stress of environment (Nazki *et al.*, 1986).

The overall average of zona reticularis in ages (one month, two month, six month and two years) was (27.32±2.31, 31.44±3.21, 44.22±3.1, 59.87±4.3) um respectively table 1. In age one day showed zona reticularis mixed with zona fasciculate.

Garven (1968) reported a definite cortex differentiation in to three zones, the zona reticularis developing last in children. Finerty and Cowdry, (1962) was suggested that zona reticularis of adult cortex was a remnant of fetal cortex. The other ages reported significant differences ( $P \leq 0.05$ ) between different ages. Singh *et al.*, (1986) seen could not make sharp distinction between zona fasciculata and reticularis and found that the size of the cortex was formed by the combined zones of zona fasciculata and reticularis.

The overall average of medulla thickness in ages (one day, one month, two month, six month and two years) was (39.61±3.22, 48.33±2.34, 90.51±3.66, 98.71±3.1, 115.3±4.21) um respectively table 1. The present study the medulla showed a remarkable increase in size of t medulla with postnatal age advanced till two years.

### References

Al-Taay, M.M.K. (2007). Anatomical and Histological study of thyroid and parathyroid glands in Iraqi buffalo (*Bubalus bubalis*) with referring to the seasonal changes. M.Sc. Thesis. College of Veterinary Medicine. Baghdad. Iraq.

Ashok, N., K.R. Harshan and J.J. Chungath (2011). Histochemical studies on the developing adrenal gland in crossbred goat fetuses (*Capra hircus*). *Tamil Nadu Journal of Veterinary and Animal Sciences.*, **7**: 193-197.

Bacha, W.J. and L.M. Bacha (2000). Color atlas of veterinary histology 2<sup>nd</sup> ed. Lippin coot Williams and wilkins.

Bacha, W.J. and L.M. Wood (1990). Color atlas of veterinary histology Lea and Febiger Philadelphia. London. 178-185.

Chibuzo, G.A. (2006). The teeth in: Ruminant Dissection Guide: A Regional Approach in the Goats. 2nd revised ed. Beth-Bekka Academic Publishers, Maiduguri Nigeria. 59-61.

Dellman, H.D. (1993). Textbook of Veterinary Histology. 4th Edition, Lea and Febiger, Williams and Wilkins, A Waverly Company. 280-282.

Field, A. (2013). Discovering statistics using IBM SPSS statistics, Sage.

Finerty, J.C. and E.V. Cowdry (1962). A Text Book of Histology.

- Garven, H.S.D. (1968). A students Histology 2nd Edition, E and S. Living stone Limited, Edinburgh and London.
- Gursoy, O., E. Pekel, L. Ozcan, O. Torun and V. Timon (1993). Comparisons of production traits of Ceylanpinar Awassi sheep with top producing ewes of national flocks in the GAP area. II.
- Hailat, N. (2005). Small ruminant breeds of Jordan. In Characterization of small ruminant breeds in West Asia and North Africa. *Small Ruminants Research.*, **1**: 31-62.
- Humayun, K.A.K.M., M. Aoyama and S. Sugita (2012). Morphological and Histological studies on the adrenal gland (*Gallus domesticus*). *J. Poult. Sci.*, **49**: 39-45
- Junqueira, L.C., J. Carneiro and R.O. Kelly (1998). Basic histology. 9<sup>th</sup> ed McGraw and Hill, NewYork, 387-395.
- McDonald, L.E. (2003). Veterinary Endocrinology and Reproduction. 5<sup>th</sup> ed. Iowa State Press, Iowa. 165-201.
- Nazki, A.R., S.P.S. Sinha, S.P.S. Sodhi and P.J.S. Rattan (1986). Effect of seasonal environments on the adrenal, cortical and thyroidal hormones of sheep. *Ind. J. Anim. Sci.*, **56(3)**: 327-330.
- Paul, B., S. Sarkar, M.N. Islam and R. Das (2016). Morphological and histological investigations on the adrenal glands in black Bengal goat (*Capra hircus*). *J. Sylhet. Agril. Univ.*, **3(2)**: 181-187.
- Prasad, G. and R.D. Sinha (1981a). Micrometric observations on the adrenal glands of domestic animals. *Indian Journal of Animal Sciences.*, **51(12)**: 1144-1147.
- Prasad, G. and R.D. Sinha (1981b). Histological observations on the adrenal medulla of domestic animals. *Indian Journal of Animal Science.*, **51(4)**: 446-454.
- Prasad, G. and R.C.P. Yadava (1972). Histological studies on the fibrous architecture of the adrenal glands of Indian buffalo. *Indian J. of Animal Science.*, **42(7)**: 472-475.
- Singh, D., P. Prakash and V.D. Goel (1986). A quantitative structural changes in the adrenal gland of gonadotomized goats. *Indian Veterinary Journal.*, **63**: 732-736.
- Singh, O., P.S. Malhi and J. Singh (1999). Distribution of enzymes and lipids in the adrenal gland of the buffalo (*Bubalis bubalis*). *Buffalo J.*, **15(3)**: 385-389.